

Awake coronary artery bypass grafting under thoracic epidural anesthesia: great impact on off-pump coronary revascularization and fast-track recovery

Go Watanabe^{*}, Shigeyuki Tomita, Shojiro Yamaguchi, Noriyoshi Yashiki

Department of General and Cardiothoracic Surgery, Kanazawa University, 13-1 Takara-machi, Kanazawa 920-8640, Japan

Received 22 July 2010; received in revised form 11 January 2011; accepted 12 January 2011; Available online 3 April 2011

Abstract

Objective: The ultimate goal of minimally invasive coronary artery bypass grafting (CABG) is day surgery. We evaluated the potential of a new awake CABG protocol using only epidural anesthesia in realizing day surgery. **Methods:** Seventy-two patients who underwent awake off-pump CABG (OPCAB) in our institute from March 2003 were studied. One day before surgery, an epidural catheter was placed at the Th1–2 interspace. On the day of surgery, local anesthetics were delivered via the catheter to provide a level of epidural block from C6 to Th8. Among 1260 patients who underwent OPCAB under general anesthesia (GA) during this study period, 67 of them who matched for age and gender with the awake OPCAB group were selected as controls (GA group). Postoperative fast-track recovery was evaluated. **Results:** In 67 of the 72 patients (93%), awake OPCAB under consciousness and spontaneous breathing was fully accomplished. Five patients had to be administered GA. Ten patients (14.9%) were able to leave the operating room in a wheelchair. The time to drink water, the time to walk, and hospital stay were significantly shorter in awake OPCAB group than in the GA group. There were no operative and postoperative complications or deaths. **Conclusions:** Despite the presence of severe preoperative comorbidities in this series, good surgical outcome was obtained. Almost all the patients were able to drink water and walk very soon after surgery, suggesting the potential of this protocol as one-day or day surgery. Awake OPCAB is a promising modality of ultra-minimally invasive cardiac surgery.

© 2011 European Association for Cardio-Thoracic Surgery. Published by Elsevier B.V. All rights reserved.

Keywords: OPCAB; Thoracic epidural anesthesia; Awake

1. Introduction

With the advantages of low mortality and morbidity as well as good long-term outcome, coronary artery bypass grafting (CABG) has been recognized to be superior to even percutaneous coronary intervention (PCI). Moreover, surgical techniques, not requiring cardiopulmonary bypass (off-pump) have been widely used in recent years, and over 50% of CABGs in Japan are now conducted using the off-pump technique [1]. The database in Japan has shown extremely good results, with mortality around 1% for primary CABGs. Furthermore, many reports have shown a decrease in perioperative complications such as cerebral infarction and renal failure by the adoption of off-pump CABG (OPCAB) [2].

With the focus on coronary vasodilating effect and sympathoinhibitory effect with higher thoracic epidural anesthesia (TEA), the approach on ischemic heart disease (IHD) has been reported by Blomberg et al. [3]. CABG with

only TEA will eliminate stress on the heart; this means that TEA is the ideal anesthesia for cardiac surgery.

Over the past years, we have conducted OPCAB combined with epidural anesthesia in an attempt to reduce general anesthetics and achieve early extubation [4]. In the present study, we used TEA only without general anesthesia, and adopted an anterior approach for CABG. The first large series of awake OPCAB was reported by Karagoz et al. [5] in 2000; Aybek et al. reported the possible operative techniques using complete median sternotomy in awake OPCAB [6]. Most of the reported cases were single-vessel bypasses. We modified their techniques to perform multi-vessel bypasses using multiple arterial conduits. We herein report the feasibility of awake OPCAB with TEA for fast-track patient recovery.

2. Methods

2.1. Patients

Seventy-two patients who underwent awake off-pump CABG (OPCAB) via an anterior approach in our institute

^{*} Corresponding author. Tel.: +81 76 265 2355; fax: +81 76 222 6833.
E-mail address: watago6633@gmail.com (G. Watanabe).

between March 2003 and May 2009 were studied. These patients constituted 5.7% of the 1260 OPCAB conducted during the same period. All study participants provided informed consent.

2.2. Surgical indications

Patient selection criteria were as follows: (1) patients with cerebrovascular impairment, either symptomatic or preoperative single photon emission computed tomography (SPECT) findings showing ischemia and/or transient ischemic attack (TIA) or stenosis in unilateral carotid artery, who are at risk of cerebral ischemia due to a blood pressure decrease during surgery; (2) patients with chronic pulmonary diseases who may not tolerate general anesthesia, specifically patients on home oxygen therapy and those with preoperative lung function test showing forced expiratory volume in 1 second (FEV) <1000 ml or diffusing capacity for carbon monoxide (DL_{CO}) $\leq 40\%$ or oxygen saturation (SpO_2) $\leq 95\%$; (3) patients who request rapid discharge and return to normal daily life; and (4) the procedure is predicted to be completed within 3 h. awake off-pump CABG (OPCAB) (AOCAB) was indicated for patients who fulfilled at least one of the first three criteria and also the fourth criterion.

2.3. Anesthesia

One day before surgery, an epidural catheter was placed at the T1–2 or T2–3 interspace, and the position of the tip was confirmed by contrast imaging. On the day of surgery, a mixture of 40 ml of 2% lidocaine and 5 mg of fentanyl citrate was infused continuously via the epidural catheter at a speed of 20 ml h⁻¹, to provide sympathetic, motor, and sensory block from the 6th cervical (C6) to the 8th thoracic (Th8) level. Surgery was conducted with intra-operative monitoring for analgesia. Since general anesthesia was not used, the patient remained conscious and surgery was started without endotracheal intubation.

2.4. Approach

For single-vessel disease of the left anterior descending (LAD) coronary artery, the rib cage lifting technique was used according to Karagoz et al. [5], in which a low partial sternotomy was made, through which the left rib cage was lifted and the internal thoracic artery was anastomosed to the LAD. For patients with severe chronic obstructive lung disease (COLD), single-vessel bypass grafting was conducted without incising the pleural cavity in order to reduce the risk of opening the pleura. Through a mini-incision made below by the xyphoid process, the gastroepiploic artery (GEA) was harvested and anastomosed to the LAD [4]. For patients with multi-vessel diseases, the OPCAB technique for total revascularization via a full median sternotomy was used.

2.5. Graft selection

The primary strategy was to anastomose the left internal thoracic artery (ITA) to the LAD branch. The left ITA was harvested using skeletonization technique, according to the conventional method with slight modification. The radial

artery (RA) was chosen as the second graft. To harvest the RA graft, either additional local anesthesia of the antebrachial region or axillary block was used. The GEA was used as the third graft. High epidural block was sufficient for harvesting the GEA graft. Almost all patients did not report pain even with stomach traction. The GEA was skeletonized to remove the surrounding fat tissue and the satellite veins (GEA skeletonizing method) [7]. The saphenous vein graft (SVG) was harvested under additional local anesthesia and through a small incision.

2.6. Parameters analyzed

First the preoperative patient characteristics, operative details, and surgical results (including complications) in the awake OPCAB group were examined. We have monitored intra-operative PaO₂, PaCO₂, pulmonary artery pressure, and cardiac index (CI) using a Swan–Ganz catheter. Next, a matched study was conducted by selecting a group of patients matched for age and gender with the awake OPCAB group, who underwent OPCAB under general anesthesia during the same period (GA group). Surgical outcome and postoperative fast-track recovery (postoperative water drinking, walking, and discharge) was evaluated by comparing the two groups.

2.7. Statistical analysis

Data were analyzed using Microsoft Access, Microsoft Excel (Redmond, WA, USA) and Statview (Cary, NC, USA). The baseline characteristics and hospital outcomes for the two groups were compared using χ^2 test and categorical data and two-tailed Mann–Whitney *U*-test for continuous variables. Data are reported as mean \pm standard deviation (SD) in the text and tables. Statistical significance was defined as a *p* value less than 0.05.

3. Results

3.1. Preoperative characteristics of patient group

The 72 patients who underwent awake OPCAB comprised 66 men and six women with a mean age of 68 \pm 11 (Table 1). The coronary artery stenotic lesions were classified as 1-vessel disease in 17 patients, two-vessel disease in 22, three-vessel disease in 28, and left main trunk (LMT) disease in 35. Before surgery, 42 patients had a history of cerebral infarction and significant carotid artery stenosis or obstruction; 21 patients were wet cases with severe COLD; nine patients had arteriosclerosis obliterans. Preoperative left ventricular ejection fraction (LVEF) was 61.3 \pm 14%.

Table 1. Patient characteristics.

Age	68 \pm 11 years
Sex (M/F)	66/6 = M/F
Left ventricular ejection fraction	61 \pm 14%
Preoperative co-morbidities	
Cerebrovascular event (including recent cerebral hemorrhage)	42
Chronic obstructive lung disease	21
Arteriosclerosis obliterans	9
Chronic renal failure	4

Table 2. Operative detail.

Grafts used	
Left internal thoracic artery	64
Right internal thoracic artery	8
Right gastroepiploic artery	21
Radial artery	38
Y composite	18
I composite	11
Aorta	9
Saphenous vein graft	27
Target vessels	
Left anterior descending coronary artery	72
Diagonal branch	26
Circumflex artery	38
Right coronary artery	38

3.2. Operative details

Fifty-seven patients underwent awake OPCAB by full sternotomy and 15 by the rib cage lifting technique [5]. Single-vessel bypass was conducted in 17 patients, two-vessel bypasses in 21, three-vessel bypass in 23, 4-vessel bypass in nine, and five-vessel bypass in two. For all bypasses, the mean operation time was 171 ± 49 min and the mean number of bypasses was 2.42 ± 1.0 . For multi-vessel bypasses (two or more vessels), the mean operation time was 174 ± 37.6 min, and the mean number of bypasses was 2.9 ± 0.83 . Details of the arterial conduits used and target coronary arteries are shown in Table 2.

Intra-operative respiratory and hemodynamic parameters in awake OPCAB are shown in Table 3.

3.3. Postoperative recovery

Awake OPCAB was fully accomplished in 67 of 72 patients (93%) while five patients (7%) had to be administered GA (see 'intra-operative conversion and TEA-related postoperative complications'). All 72 patients (100%) were completely conscious and breathing spontaneously with an oxygen mask at the end of surgery in the operation room (Fig. 1).

3.4. Intra-operative conversion and TEA-related postoperative complications

During surgery, anesthesia problems or respiratory complications occurred in five of 72 patients, necessitating conversion to general anesthesia with endotracheal intubation. The causes for this conversion were inadequate epidural anesthesia in two patients, suspected local anesthesia intoxication in two, and difficulties in maintaining spontaneous

Table 3. Intraoperative respiratory and hemodynamic parameter in awake OPCAB ($n = 67$).

PaO ₂	95 ± 20 Torr
PaCO ₂	47 ± 5.2 Torr
Heart rate	66 ± 9.9/min
Systemic blood pressure	89 ± 17 mmHg
Diastolic blood pressure	53 ± 9.8 mmHg
Systolic pulmonary artery pressure	29 ± 4.0 mmHg
Diastolic pulmonary artery pressure	15 ± 3.1 mmHg
Cardiac Index	2.9 ± 0.4 l/min mm ²

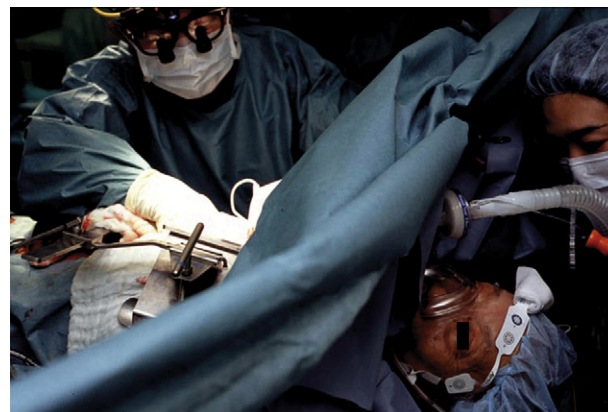


Fig. 1. During the awake OPCAB surgery, the patient is completely conscious and maintaining spontaneous respiration.

respiration due to bilateral pneumothorax caused by pleural opening in one.

3.5. Surgical outcome

There were no operative and in-hospital deaths, no severe postoperative complications such as respiratory tract complications, rebleeding, cerebral infarction, and heart failure in both the groups. Postoperative atrial fibrillation occurred in five of 72 patients (6.9%) in the awake OPCAB group and 15 of 67 (21%) in the GA group ($p < 0.05$).

3.6. Fast-track recovery

Ten patients (14.9%) were able to leave the operating room in a wheelchair (Fig. 2).

Postoperative recovery was compared between 67 patients in the awake OPCAB group and age-matched patients in the GA group. The time to drinking water was significantly shorter ($p < 0.05$) in the awake OPCAB group (4.1 ± 2.9 h) than in the GA group (15.1 ± 3.7 h). The time to walking also tended to be significantly shorter ($p < 0.05$) in the awake OPCAB group (8.2 ± 2.9 h) than in the GA group

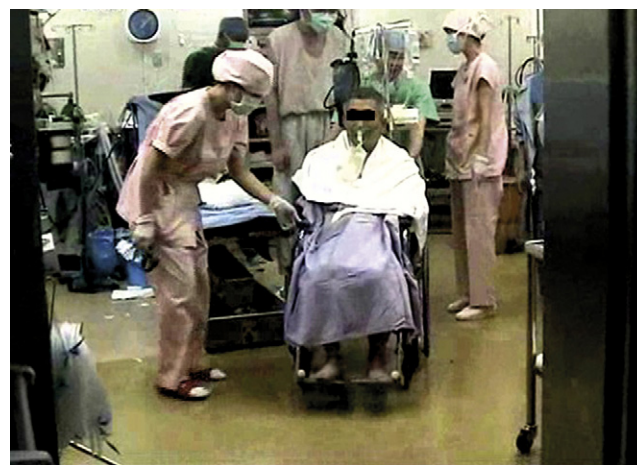

Fig. 2. The patient is completely awake, leaving the operation room in a wheelchair.

(18.9 ± 6.1 h). The postoperative hospital stay was 9.0 ± 1.5 days in the awake OPCAB group and 15.5 ± 1.3 days in the GA group, also with a significant difference ($p < 0.05$).

4. Discussion

The advantages of awake OPCAB have already been reported by Karagoz et al. [5]. The effects on hemodynamics are depression on heart rate and blood pressure and stabilizing the cardiac function after blocking the sympathetic nerve cardiac branch. It makes a stress-free situation on patients during the surgery; therefore, there is heart rate and systemic blood pressure depression, this further depresses the double product. Accordingly, cardiac oxygen consumption will be lowered, and coronary artery and internal mammary artery become dilated. With the focus on vasodilating effect and inhibition of sympathetic nerve fore in TEA, this TEA is the ideal anesthesia for CABG. Furthermore, ensuring consciousness will be a good monitoring for cerebral perfusion, which allows early detection on neurological complications and enables proper treatment. This procedure is effective for cases with high-risk cerebral ischemia and cerebrovascular lesion. It is also good for cases where general anesthesia needs to be avoided, such as in respiratory insufficiency cases or where there is a high probability of complication.

4.1. Necessity of fast-track awake CABG

The advent of an off-pump technique has reduced the postoperative complications and surgical mortality of CABG [8,9]. Off-pump CABG is especially effective for elderly patients and patients with comorbidities before surgery [10]. Although the usefulness of OPCAB has been proven and surgery can be conducted safely even in serious cases, some limitations remain. In patients with severe carotid artery stenosis before surgery, the cerebral blood flow autoregulation mechanism is impaired, and cerebral infarction of the watershed type has been observed due to blood pressure decreasing during surgery [11]. Moreover, in patients with a history of severe cerebral infarction, GA may trigger impairment of cognitive function; especially, dementia may progress in elderly patients. In addition, patients with severe respiratory failure are at risk of respiratory complications with GA. Even among patients who have no comorbidities before surgery, some desire early discharge because of social situation. Therefore, for cardiac surgeons and anesthesiologists specializing in cardiac surgeries, there is a pressing need to develop modalities that allow early social rehabilitation after surgery and avoid deterioration of cognitive function associated with GA.

Our present series proves that with an adequate level of anesthesia by TEA, it is possible to conduct OPCAB via a full sternotomy under spontaneous breathing in 93% of the patients without endotracheal intubation or artificial ventilation in this report. Although our patients possessed many risk factors indicated by the comorbidities before surgery, we achieved zero operative death and no serious complications. All the patients recovered with an uneventful postoperative

course, proving that awake OPCAB is a safe and effective surgical technique. Compared to those that are in the GA group during the same period, patients in the awake OPCAB group have revealed significantly lower postoperative atrial fibrillation rate and are able to start drinking water and walking at a significantly earlier time.

Over the past years, we have conducted awake OPCAB using TEA, and evaluated the usefulness of this method regarding postoperative neurocognitive function [12]. Particularly in surgery on a beating heart, TEA is known to suppress the sympathetic nerve excitation of the heart and dilate the coronary artery [3,13]. In the present series, the heart rate was stabilized at around 65 and the suppressed heart rate was maintained satisfactorily without using beta blockers. The systolic blood pressure was also maintained almost constantly at a mean of 65 mmHg, showing that TEA adequately suppresses the distal sympathetic excitation to the heart. Karagoz et al. [5] also observed a similar tendency of decrease in heart rate and blood pressure during surgery. These effects probably inhibit the double product and reduce myocardial oxygen consumption, and as a result suppress intra-operative events due to ischemia. Kirnő et al. [13] reported that the arrhythmia threshold was elevated by high epidural anesthesia. Yashiki et al. [14] reported that in awake OPCAB, as there is no vagal inhibition, vagal dominance can be maintained after surgery. This may be associated with the lower incidence of postoperative atrial fibrillation. For OPCAB in which the coronary artery is transiently blocked, this method is highly effective from the viewpoint of preventing arrhythmia associated with myocardial ischemia. At first we used only one epidural catheter placed in the T1–2 interspace, but some patients complained of strong epigastric pain after surgery. We therefore placed one more epidural catheter in the T5–6 interspace, and delivered postoperative analgesia mainly via the lower catheter. As a result, the level of anesthesia was extended reliably, the doses of local anesthetics were reduced, and postoperative pain relief was greatly improved. The incidence of epidural hematoma, which is a complication of TEA, was extremely low. Placement of the catheter one day before surgery prevents the development of serious symptoms [15].

4.2. Harvesting of arterial conduits, prevention, and bailout technique from pneumothorax

4.2.1. Internal thoracic artery graft

Caution has to be taken during isolation of the ITA. Careless use of a cautery knife may perforate the right parietal pleura, causing iatrogenic pneumothorax. We modified the harvesting technique to separate only the artery from the pleura by the skeletonization method using a cautery knife. Since then, we have almost not observed pneumothorax. Even in the rare case that pneumothorax occurs, we proposed to use a polyglycolic acid (PGA) sheet (Neoveil; Gunze, Kyoto, Japan) and fibrin glue to repair the parietal pleura at the site of damage [16]. When pneumothorax or pleural perforation occurs, insertion of a small drain and applying suction can repair the pneumothorax and normalize the respiratory condition. Such *in situ* graft can be procured sufficiently by careful harvesting, and even if a complication such as pleural perforation occurs, recovery can

be achieved easily. Kirali et al. [17] reported seven cases of awake OPCAB using bilateral ITAs and encountered no pneumothorax. Aybek et al. [6] reported possible operative techniques through full sternotomy in nine cases of awake OPCAB. Kirali et al. [17] also reported bilateral ITA harvest in seven cases of awake OPCAB. However, the right ITA takedown has a high risk of right pneumothorax, therefore we do not use bilateral ITAs.

4.2.2. Gastroepiploic artery graft

In our series, the GEA graft was effectively used as an option of arterial conduit. By harvesting the GEA graft through extending the incision to the upper abdomen, no pain is reported and this method obviates the problem of respiratory depression by laparotomy. The important point is to make a hole as small as possible through the diaphragm.

4.2.3. RA graft

For RA graft harvesting, extension of anesthesia to C5 level is required, although this level of extension is not achieved in some patients. However, by using the recently developed ultrasound-guided nerve block [18], safe and reliable anesthesia levels can be achieved even in these patients.

4.3. Intra-operative respiratory and hemodynamic function

Due to complete epidural block, there is no intercostal muscle acting. The patients are breathing only through the diaphragm. According to intra-operative respiratory function parameter, there was no sign of hypercapnia or dyspnea. This can be sufficient during awake OPCAB even in severe COPD patients.

Coronary artery anastomoses can be performed as in conventional OPCAB. In the present series, we observed no severe deterioration of hemodynamics due to myocardial ischemia during coronary artery anastomoses and no arrhythmogenicity. The sympathetic nerve block of TEA probably contributes greatly to these beneficial results. During coronary artery anastomosis, we used a coronary active perfusion system (CAPS: Watanabe Ensuring System) [19] during coronary artery clamping to maintain myocardial blood flow distal to the anastomosis. This technique also contributes towards obtaining good results.

4.4. Postoperative fast-track recovery

In patients who accomplished awake OPCAB, not only were they completely awake in the operation room and able to return to the general wards, the postoperative consciousness level was so high that some patients left the operation room in a wheelchair. Compared to the GA group of the same period, the awake OPCAB group was able to start drinking water and walking at a significantly earlier time. Furthermore, since there was no pharyngeal pain due to endotracheal intubation, aspiration was not observed. The patients were able to return to normal daily life at a very early stage. The length of hospital stay was also significantly shorter in the awake OPCAB group compared to the GA group of the same period. The postoperative neurocognitive

function recovery was significantly better in the awake OPCAB group compared to that in the GA group [20].

5. Conclusion

Awake OPCAB using TEA obviates the traumas associated with endotracheal intubation and GA. Although the procedure requires advanced anesthetic technique and high-level surgical competence in terms of skill and speed, this surgical modality opens the door of surgical treatment for high-risk patients with serious diseases in whom conventional CABG was not feasible, as well as allows patients who opt for early recovery to return to normal living early after surgery with markedly improved quality of life (QOL). Awake OPCAB under thoracic epidural anesthesia is a promising modality of ultra-minimally invasive cardiac surgery.

6. Limitation

During anticoagulant treatment, this technique should be avoided because of the risk of epidural hematoma. We need to avoid prolonged anesthesia more than 3 h due to local anesthetic intoxication.

References

- [1] Sezai Y, Orime Y, Tsukamoto S. Coronary artery surgery results 2005 in Japan. *Ann Thorac Cardiovasc Surg* 2007;13:220–3.
- [2] Kobayashi J. Off-pump coronary artery bypass grafting in Japan. *Nippon Geka Gakkai Zasshi* 2006;107:9–14.
- [3] Blomberg S, Emanuelsson S, Ricksten SE. Thoracic epidural anesthesia and central hemodynamics in patients with unstable angina pectoris. *Anesth Analg* 1989;69:558–62.
- [4] Watanabe G, Yamaguchi S, Tomita S, Ohtake H. Awake subxyphoid minimally invasive direct coronary artery bypass grafting yielded minimum invasive cardiac surgery for high risk patients. *Interactive Cardiovasc Thorac Surg* 2008;7:910–2.
- [5] Karagoz HY, Sönmez B, Bakkaloglu B, Kurtoglu M, Erdinç M, Türkeli A, Bayazit K. Coronary artery bypass grafting in the conscious patient without endotracheal general anesthesia. *Ann Thorac Surg* 2000;70:91–6.
- [6] Aybek T, Kessler P, Dogan S, Neidhart G, Khan MF, Wimmer-Greinecker G, Moritz A. Awake coronary artery bypass grafting: utopia or reality? *Ann Thorac Surg* 2003;75:1165–70.
- [7] Kamiya H, Watanabe G, Takemura H, Tomita S, Nagamine H, Kanamori T. Total arterial revascularization with composite skeletonized gastroepiploic artery graft in off-pump coronary artery bypass grafting. *Thoracic Cardiovasc Surg* 2004;127:1151–7.
- [8] Puskas JD, Kilgo PD, Lattouf OM, Thourani VH, Cooper WA, Vassiliades TA, Chen EP, Vega JD, Guyton RA. Off-pump coronary bypass provides reduced mortality and morbidity and equivalent 10-year survival. *Ann Thorac Surg* 2008;86:1139–46. discussion 1146.
- [9] Zhang L, Boyce SW, Hill PC, Sun X, Lee A, Haile E, Garcia JM, Corso PJ. Off-pump coronary artery bypass grafting improves in-hospital mortality in patients with dialysis-dependent renal failure. *Cardiovasc Revasc Med* 2009;10:12–6.
- [10] Meco M, Biraghi T, Panisi P, Casselman F, Cossetta D, Cirri S. Aortocoronary bypass grafting in high-risk patients over 75 years. Propensity score analysis of on versus off-pump, early and midterm results. *J Cardiovasc Surg (Torino)* 2007;48:339–47.
- [11] Selnes OA, Goldsborough MA, Borowicz LM, McKhann GM. Neurobehavioral sequelae of cardiopulmonary bypass. *Lancet* 1999;8:1601–6.
- [12] Tomita S, Watanabe G. Coronary artery bypass surgery using thoracic epidural anesthesia leads patients to early ambulation. *J Jpn Coron Assoc* 2004;10:163–6.

- [13] Kirnö K, Friberg P, Grzegorzczak A, Milocco I, Ricksten SE, Lundin S. Thoracic epidural anesthesia during coronary artery bypass surgery: effects on cardiac sympathetic activity, myocardial blood flow and metabolism, and central hemodynamics. *Anesth Analg* 1994;79:1075–81.
- [14] Yashiki N, Watanabe G, Tomita S, Nishida S, Yasuda T, Arai S. Thoracic epidural anesthesia for coronary bypass surgery affects autonomic neural function and arrhythmias. *Innovations* 2005;1:83–7.
- [15] Ho AN, Chung DC, Joynt GM. Neuraxial blockade and hematoma in cardiac surgery* estimating the risk of a rare adverse event that has not (yet) occurred. *CHEST* 2000;117:551–5.
- [16] Kato Y, Matsumoto I, Tomita S, Watanabe G. A novel technique to prevent intra-operative pneumothorax in awake coronary artery bypass grafting: biomaterial neo-pleura. *Eur J Cardiothorac Surg* 2009;35:37–42.
- [17] Kirali K, Koçak T, Güzelmeriç F, Göksedef D, Kayalar N, Yakut C. Off-pump awake coronary revascularization using bilateral internal thoracic arteries. *Ann Thorac Surg* 2004;78:1598–603.
- [18] Eichenberger U, Stöckli S, Marhofer P, Huber G, Willmann P, Kettner SC, Pleiner J, Curatolo M, Kapral S. Minimal local anesthetic volume for peripheral nerve block: a new ultrasound-guided, nerve dimension-based method. *Reg Anesth Pain Med* 2009;34:242–6.
- [19] Watanabe G, Kamiya H, Nagamine H, Tomita S, Koshida Y, Nishida S, Ohtake H, Arai S, Yasuda T. Off-pump CABG with synchronized arterial flow ensuring system. *Ann Thorac Surg* 2005;80:1893–7.
- [20] Tomita S, Watanabe G. Awake off-pump CABG using high thoracic epidural anesthesia: effect on postoperative neuro-cognitive function. *Anesth Analg*, in press.